



Comparing Outcomes in Orthognathic Surgery Using Clear Aligners Versus Conventional Fixed Appliances

Hadyn Kankam, BA, MB,* Sarika Madari, BA,* Rajendra Sawh-Martinez, MD, MHS,*
Karl C. Bruckman, MD, DDS,* and Derek M. Steinbacher, MD, DMD*[†]

Purpose: Orthognathic surgery for dentofacial deformities is typically preceded and followed by orthodontic treatment. Traditionally, orthodontic hardware is secured to the dentition to allow dental movement and stabilization. Clear-aligner therapy (eg, Invisalign) provides an aesthetic alternative, consisting of a series of transparent trays. Its use has not been described in complex triple-jaw orthognathic surgery. The purpose of this study is to evaluate perioperative outcomes and 3-dimensionally quantify postoperative edema in Invisalign patients undergoing triple-jaw orthognathic procedures, comparing this to patients treated with conventional fixed appliances. The surgical approach to patients with clear-aligners is also outlined.

Methods: The authors conducted a retrospective chart review and 3-dimensional morphometric study of Invisalign patients undergoing triple-jaw surgery (LeFort I osteotomy, bilateral sagittal split osteotomy, and genioplasty). An identical assessment of demographically matched patients treated with conventional fixed appliances was performed and compared with the Invisalign group.

Results: Thirty-three patients, with a mean age of 19.99 years, were included: 13 with Invisalign and 20 with conventional fixed appliances. No significant difference was observed in operating time, concurrent extraction of teeth, fat grafting, duration of hospital stay, diet advancement, and use of narcotic analgesics between the 2 groups. Nine patients had sufficient 3-dimensional images for volumetric analysis (4 with Invisalign and 5 with conventional fixed appliances). Postoperative edema was not significantly different ($P=0.712$) when comparing conventional fixed appliances ($44.29 \pm 23.16 \text{ cm}^3$) to Invisalign ($37.36 \pm 31.19 \text{ cm}^3$).

Conclusion: The present study demonstrates that complex multiple-jaw orthognathic procedures can be successfully performed in Invisalign patients. Perioperative and short-term clinical outcomes are not compromised.

Key Words: Invisalign, orthognathic surgery, rhinoplasty

(*J Craniofac Surg* 2019;30: 1488–1491)

Orthognathic surgery is frequently performed for the correction of dentofacial abnormalities, with over 10,000 procedures performed in the United States in 2008.¹ This intervention aims to improve several aesthetic and functional parameters by addressing skeletal discrepancies of the jaw. The treatment plan often incorporates an orthodontic regime both before and after the procedure itself. Traditionally, fixed orthodontia, consisting of conventional fixed appliances and arch wires, have been applied.^{2,3} These devices facilitate optimal dental positioning by decomensating the premorbid state, levelling, and aligning the teeth. The traditional orthodontic hardware can then be used for intermaxillary fixation and stabilization of the dental arches postoperatively. However, conventional fixed appliances are poorly tolerated in certain patients.^{4,5}

Over the previous 2 decades, clear aligners, such as Invisalign (Align Technology Inc, San José, CA), have transformed the field of orthodontics. As an alternative to fixed appliances, they provide several advantages, with greater patient satisfaction a key factor.⁶ Typically, the therapy involves a series of removable transparent plastic trays worn for 20 to 22 hours each day.⁷ Although they are indicated for the treatment of mild malocclusions and crowding, the use of clear-aligner systems in cases that ultimately require surgery is controversial.^{8,9} Several challenges exist during the orthodontic phase and intraoperatively.¹⁰ Furthermore, complex triple-jaw orthognathic surgery (LeFort I osteotomy, bilateral sagittal split osteotomy [BSSO], and genioplasty) in a patient treated with clear aligners is yet to be described.

In the present study, we review perioperative outcomes and postoperative edema (employing a three-dimensional [3D] morphometric analysis) of Invisalign patients undergoing triple-jaw surgery, comparing them to their counterparts with conventional fixed appliances. We hypothesize that there are no significant differences between these 2 cohorts in any of the measured parameters. The surgical approach to clear-aligner patients is also described.

METHODS

Patient Selection and Data Collection

This study was performed in accordance with the Yale University Human Investigation Committee (HIC ID: 1101007932) and is in accordance with the Helsinki Declaration. Patients who underwent triple-jaw surgery, performed by the senior author (DMS) from January 2015 to August 2017, and were treated with Invisalign were included. A demographically matched control cohort consisted of subjects who had the same procedure over the same time period by the senior author but donned conventional fixed appliances instead. Exclusion criteria included any patients with lingual fixed appliances and those who underwent other concurrent craniofacial surgeries.

From the *Department of Surgery, Section of Plastic Surgery; and [†]Division of Oral and Maxillofacial Surgery, Yale University School of Medicine, New Haven, CT.

Received February 25, 2019.

Accepted for publication March 20, 2019.

Address correspondence and reprint requests to Derek M. Steinbacher, MD, DMD, 3rd Floor, Boardman Building, 330 Cedar Street, New Haven, CT 06520; E-mail: derek.steinbacher@yale.edu

Presented at NESPS, October 2018.

The authors report no conflicts of interest.

Supplemental digital contents are available for this article. Direct URL citations appear in the printed text and are provided in the HTML and PDF versions of this article on the journal's Web site (www.jcraniofacialsurgery.com).

Copyright © 2019 by Mutaz B. Habal, MD

ISSN: 1049-2275

DOI: 10.1097/SCS.0000000000005572

Demographic details were recorded including age, sex, body mass index, and occlusal diagnosis. Perioperative information was searched for operating time, concurrent teeth extraction, fat grafting, duration of hospital stay, diet advancement, and use of narcotic analgesics as an inpatient.

Surgical Technique: Triple-Jaw Orthognathic Surgery in the Invisalign Patient

Successful orthognathic procedures in Invisalign patients require effective collaboration between the surgeon and orthodontist, as outlined in our previous article.¹¹ Following a series of examinations and investigations, a set of presurgical active and passive aligners are developed, with the latter worn in the few weeks immediately preceding the procedure (Fig. 1). Virtual surgical planning is performed using 3D stereolithography (STL) dental arch models, with stone models available as an alternative. If a discrepancy in the transverse diameter of the maxilla is noted, digital (3D STL models) or hand (stone models) segmentation is employed to find an optimal occlusion.

During the procedure, in a mandible-first case, an intermediate splint accommodates the original maxillary position, following BSSO. A “splint-within-a-splint” may be applied, in a maxilla-first segmental case. Six 8 mm orthodontic bone anchor screws (OBAS) are inserted at the mucogingival line, with 1 each placed between the maxillary and mandibular central incisors and one each between the second premolar and first molar in all 4 quadrants. Upon completion of the BSSO and LeFort I osteotomy (with or without segmentation), the final splint is secured to the OBAS, in 3 locations, with wires. Osseous genioplasty is performed transorally, with subsequent layered closure of the mandible and maxilla.

Postoperatively, the final splint remains in situ for 3 to 6 weeks. The aligners are developed by Align Technology, with input from the orthodontist, using 3D STL files of the final occlusion. Orthodontic bone anchor screws may be left in place, if deemed necessary, for vertical pull or retraining of the bite (Fig. 2).

Three-Dimensional Photographic Imaging and Volumetric Analysis

Images were captured with the Vectra 3D imaging system (Canfield Scientific Inc, Fairfield, NJ), as this is standard practice for consultations before and after orthognathic procedures at our center. If a patient failed to undergo imaging during the first follow-up appointment (8–14 days postoperatively) and 6 months after the procedure, they were excluded from the analysis of volumetric change.

The 3D photographs were imported to and analyzed using Mirror medical imaging software (Canfield Scientific Inc, Fairfield, NJ). Due to the movement of skeletal structures, including the mandible and maxilla, during orthognathic surgery, preoperative 3D images could not be used as a baseline to assess postoperative

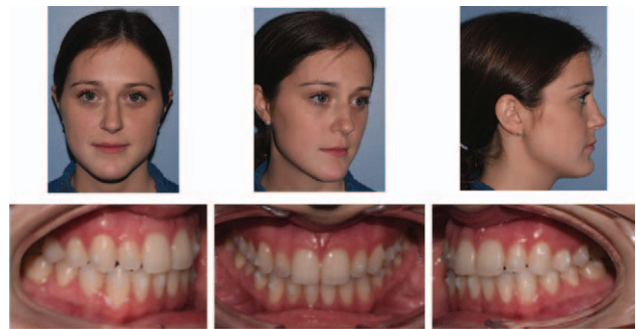

FIGURE 2. Example of postoperative clinical photographs.

edema. Therefore, images taken 6 months after the procedure provided a baseline (T0). All images were registered to an axis grid. Postoperative images from the first follow-up appointment (T1) were then superimposed on the corresponding baseline image (T0), using anatomical landmarks of the upper face and image contour. Volume differences (cm³) between the middle and lower face of superimposed images were calculated to three-dimensionally quantify postoperative edema. A single investigator (HKNK) performed analysis of all 3D photographs to eliminate error due to interoperator variability, and the process was then repeated 3 weeks later to confirm the reproducibility of the results.

Statistical Analysis

Patient demographics, perioperative outcomes, and postoperative edema were compared between the Invisalign and conventional fixed appliance cohorts. Categorical variables such as sex and extraction of teeth were analyzed with χ^2 tests, while Student *t* test was used for continuous variables. A *P* value of <0.05 was considered significant.

RESULTS

Patient Demographics and Perioperative Variables

Thirty-three patients met the inclusion criteria, 13 were treated with the Invisalign system and 20 with conventional fixed appliances (control group). The mean age of the entire cohort was 19.99 years, with a body mass index of 23.76 kg/m². These variables did not significantly differ between the 2 groups. A summary of the demographic and perioperative variables of the study population is illustrated in Table 1 (SDC, <http://links.lww.com/SCS/A507>). There was no significant difference in sex, occlusal diagnosis, operating time, extraction of teeth, duration of hospital stay, diet advancement, and use of narcotic analgesics (total number of doses, Fentanyl, Hydromorphone, Oxycodone, Hydrocodone, and Morphine) between the 2 groups. The conventional orthodontia group, though, had a significantly larger maxillary advancement with LeFort osteotomies. Each group had 7 cases of a segmental Lefort osteotomy being performed.

Postoperative Edema

Five patients with conventional fixed appliances and 4 Invisalign patients had 3D photographs taken at their first postsurgical appointment (T1) and at 6 months following the procedure (T0), and thus were included in the volumetric analysis. Table 2 (SDC, <http://links.lww.com/SCS/A507>) demonstrates the demographic and intraoperative variables of the included patients. Photographs were taken 10.80 ± 1.79 days following the procedure in patients with

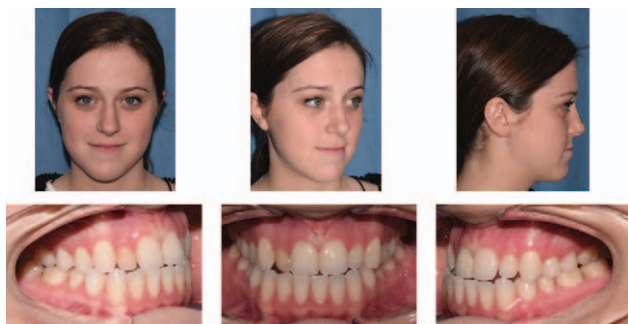

FIGURE 1. Example of preoperative clinical photographs.

conventional fixed appliances and after 11.25 ± 2.22 days for those donning Invisalign ($P = 0.745$). Postoperative edema was not significantly different between the conventional fixed appliance and Invisalign cohorts ($44.29 \pm 23.16 \text{ cm}^3$ versus $37.36 \pm 31.19 \text{ cm}^3$, $P = 0.712$).

DISCUSSION

The combination of clear-aligner therapy (eg, Invisalign) and orthognathic surgery is a novel idea, with limited evidence to date.⁸ The use of this orthodontic therapy in triple-jaw orthognathic surgery has never been described. For example, when searching PubMed and Scopus for “clear aligner and orthognathic,” 0 publications are found. Likewise, a search of “Invisalign and orthognathic” only locates 2 manuscripts. In our study, we reviewed a variety of perioperative outcomes and edema following this procedure, comparing these findings to a demographically matched control treated with conventional fixed appliances. Despite differences in the orthodontic regimens and the impact of this on surgical technique, we found no significant difference, between the 2 cohorts, in any of the parameters assessed. Therefore, the use of the Invisalign system does not compromise short-term clinical outcomes.

There are several challenges that must be considered before routinely implementing this technique. Successful treatment with this device relies on good patient compliance, as the transparent aligners are removable and should be typically worn for 20 to 22 hours each day. Intraoperative challenges include the approach to intermaxillary fixation. Fixed orthodontic appliances, composed of metal or ceramic fixed appliances, bands, and arch wires, facilitate this fixation with Kobayashi Hooks or surgical lugs.¹⁰ However, a different approach is required for the Invisalign patient. One such technique involves the application of Erich arch bars before securing the opposing arches with wires.¹² Nevertheless, the approach described herein with OBAS remains a favorable tool, as it is associated with a reduction in procedural time, fewer physician glove perforations during surgery, and improved oral hygiene relative to arch bars.¹³ Despite this, there are drawbacks to the use of these intermaxillary fixation screws, with screw loosening and dental root damage the most common complications.¹⁴ Several hybrid alternatives such as the SMARTLock Hybrid Maxillomandibular Fixation System (Stryker, Kalamazoo, MI) have now been developed.¹⁵ This device combines the principles of both arch and screw fixation. Therefore, although it may be an improvement on existing options, its limitations will be similar. Hence, the most appropriate method will be determined by patient and physician preference.

Further difficulties exist depending on the type of procedure. In the case of a segmental maxillary osteotomy, the mechanical action of fixed appliances separating the teeth prior to surgery and a continuous arch wire maintaining the postoperative dimensions of the maxilla are not present and alternative solutions must be sought.

We also noted that a higher than normal number of patient undergoing orthodontic therapy with clear aligners had dental extractions (30.8%). Upon further investigation, it was noted that these patients had the extractions performed to compensate dentally for their skeletal deformity. In these cases, a poor aesthetic outcome was achieved with orthodontic therapy alone.

However, irrespective of the challenges encountered, the present study demonstrates similar short-term clinical outcomes when Invisalign is compared with conventional fixed appliances. Furthermore, there are several benefits to support the use of clear aligners. Patients adapt to this therapy in a short period of time, with less suffering from functional impairments (particularly speech) and pain beyond the first few days of treatment.¹⁶ Clear-aligners are also better camouflaged than traditional orthodontic brackets and wires, maintaining a more aesthetic appearance. The removable

aligners can be replaced by patients with the option of delivering subsequent trays to their place of residence. This eliminates the requirement of frequent orthodontic appointments for apparatus adjustment. Azaripour et al⁶ recently reported greater patient satisfaction with Invisalign relative to fixed orthodontic appliances. Using a questionnaire, they assessed numerous factors likely to affect patient experience such as change of eating habits and impairment of general wellbeing due to their orthodontic treatment. Superior gingival health was also seen in the Invisalign group.⁶ This is particularly important since incisions placed within inflamed tissue can theoretically be prone to dehiscence, thus exposing the underlying hardware.

With regard to performing a financial analysis between clear aligners and conventional orthodontia for surgical cases, there have been no studies that directly compare the cost of these 2 modalities. This is mainly due to the lack of standardized treatment costs between providers, a wide variability in coverage from dental insurers, and the potential for increasing orthodontic costs for surgical cases. Recent survey data from the American Dental Association states that comprehensive treatment costs may range from \$4978 to 6900 for adolescents and \$5100 to 7045 for adults, irrespective of the modality.¹⁷ Data from the Invisalign website regarding costs of treatment provides a range of quotes from dental providers being \$3400 to 7100 (preinsurance).¹⁸ Thus, there are no clear cost differences between the 2.

Although the present study is limited by its retrospective design and the relatively small number of subjects included, it demonstrates that clear aligners can be successfully employed in patients undergoing complex triple-jaw orthognathic surgery. This is a novel concept with initial promising pilot results, but further studies in the form of prospective randomized-controlled trials are required to confirm these findings.


CONCLUSION

In this study, we describe the surgical approach to complex triple-jaw orthognathic surgery for the Invisalign patient. Perioperative outcomes and postoperative edema are not significantly affected when clear-aligner therapy is implemented as an alternative to conventional fixed appliances. Therefore, the use of Invisalign should not be considered a contraindication for orthognathic surgery and may be preferred by many patients given its reported benefits.

REFERENCES

1. Venugoplan SR, Nanda V, Turkistani K, et al. Discharge patterns of orthognathic surgeries in the United States. *J Oral Maxillofac Surg* 2012;70:e77–e86
2. Wirthlin JO, Shetye PR. Orthodontist's role in orthognathic surgery. *Semin Plast Surg* 2013;27:137–144
3. Williams AC, Shah H, Sandy JR, et al. Patients' motivations for treatment and their experiences of orthodontic preparation for orthognathic surgery. *J Orthod* 2005;32:191–202
4. Yao L, Xu X, Ni Z, et al. Use of Q methodology to assess the concerns of adult female individuals seeking orthodontic treatment. *Patient Prefer Adherence* 2015;9:47–55
5. Rosvall MD, Fields HW, Ziuchkovski J, et al. Attractiveness, acceptability, and value of orthodontic appliances. *Am J Orthod Dentofacial Orthop* 2009;135:276–277
6. Azaripour A, Weusmann J, Mahmoodi B, et al. Braces versus Invisalign®: gingival parameters and patients' satisfaction during treatment: a cross-sectional study. *BMC Oral Health* 2015;15:69
7. Lagravere MO, Flores-Mir C. The treatment effects of Invisalign orthodontic aligners. *J Am Dent Assoc* 2005;136:1724–1729
8. Pagani R, Signorino F, Poli PP, et al. The use of invisalign® system in the management of the orthodontic treatment before and after class III surgical approach. *Case Rep Dent* 2016;2016:9231219

9. Phan X, Ling PH. Clinical limitations of invisalign. *J Can Dent Assoc* 2007;73:263–266
10. Taub DI, Palermo V. Orthognathic surgery for the Invisalign patient. *Semin Orthod* 2017;23:99–102
11. Kankam HKN, Gupta H, Sawh-Martinez R, et al. Segmental multiple-jaw surgery without orthodontia: clear aligners alone. *Plast Reconstr Surg* 2018;142:181–184
12. Falci SG, Douglas-de-Oliveira DW, Stella PE, et al. Is the Erich arch bar the best intermaxillary fixation method in maxillofacial fractures? A systematic review. *Med Oral Patol Oral Cir Bucal* 2015;20:e494–e499
13. Qureshi AA, Reddy UK, Warad NM, et al. Intermaxillary fixation screws versus Erich arch bars in mandibular fractures: a comparative study and review of literature. *Ann Maxillofac Surg* 2016;6:25–30
14. Hashemi HM, Parhiz A. Complications using intermaxillary fixation screws. *J Oral Maxillofac Surg* 2011;69:1411–1414
15. Kendrick DE, Park CM, Fa JM, et al. Stryker smartlock hybrid maxillomandibular fixation system: clinical application, complications, and radiographic findings. *Plast Reconstr Surg* 2016;137:142e–150e
16. Nedwed V, Miethke RR. Motivation, acceptance and problems of invisalign patients. *J Orofac Orthop* 2005;66:162–173
17. American Dental Association. 2016 Survey of Dental Fees. Available at: https://aaoinfo.org/_/frequently-asked-questions/. 2019. Accessed February 2, 2019.
18. Align Technology, Inc. /Invisalign. Available at: <https://www.invisalign.com/invisalign-cost>. Accessed February 2, 2019



Think fat...fat is beautiful.