

Clockwise and Counterclockwise Le Fort I Movements Influence Nasolabial Morphology Differently

Rajendra Sawh-Martinez,
M.D.
Alex M. Lin, M.S.
Christopher R. DeSesa,
D.M.D.
Robin T. Wu, B.S.
Cyril S. Gary, B.A.
Derek M. Steinbacher,
M.D., D.M.D.
New Haven, Conn.



Background: Le Fort I maxillary advancements affect nasal proportions. However, there are no data on the three-dimensional nasal changes that occur with differential lateral plane adjustment (clockwise and counterclockwise movements) during Le Fort I maxillary advancements. This study analyzes and compares nasolabial soft-tissue changes after Le Fort I clockwise and counterclockwise repositioning.

Methods: Single-piece Le Fort I advancements were included. A retrospective study of patients split into clockwise and counterclockwise groups was performed. Preoperative and postoperative three-dimensional photographs (VECTRA 3D) were analyzed. Nasolabial anthropometric measurements were recorded using Mirror software. Statistical analysis involved paired *t* test to compare preoperative and postoperative measurements.

Results: Twenty-four patients were evaluated (12 per group), with 22 distinct nasolabial relationships measured. Counterclockwise movement showed a statistically significant increase in alar width (3.6 mm; $p < 0.001$), alar base width (1.6 mm; $p = 0.009$), oral width (3.2 mm; $p = 0.02$), and lip projection (3.4 mm; $p = 0.04$). Clockwise movement showed no statistically significant changes, with the largest position changes noted in alar width (2.7 mm; $p = 0.07$) and alar base width (1.7 mm; $p = 0.09$).

Conclusions: Clockwise and counterclockwise Le Fort I advancements have a different effect on postoperative nasolabial morphology. Counterclockwise movements exhibit significant changes, widening the alar base and width and the oral and philtral widths. The impact on the nostril morphology and columella was similar between the groups. The differential impact on nasolabial appearance is important to recognize for treatment planning and patient counseling. (*Plast. Reconstr. Surg.* 142: 1572, 2018.)

CLINICAL QUESTION/LEVEL OF EVIDENCE: Therapeutic, III.

Le Fort I maxillary advancement is a versatile procedure commonly performed to correct and manage a wide range of both dental

and midface skeletal deformities.¹ The procedure allows for movement and rotation of the maxilla in all three planes, indicating its use in conjunction with class II and III malocclusion, facial asymmetry, maxillary atrophy, and obstructive sleep apnea—correcting both functional and cosmetic irregularities.² Furthermore, it is commonly used to treat midface hypoplasia and vertical maxillary excess, the former of which affects 25 percent of cleft lip and palate patients.³

Facial aesthetic appearance is an important consideration in the assessment of surgical result.⁴ Surgical repositioning of the maxilla impacts

From the Department of Surgery, Section of Plastic Surgery, Yale University School of Medicine; and the Frank H. Netter MD School of Medicine, Quinnipiac University.

Received for publication September 29, 2017; accepted May 8, 2018.

Presented at 16th International Congress of the International Society of Craniofacial Surgery, in Tokyo, Japan, September 14 through 18, 2015; the New England Society of Plastic and Reconstructive Surgery Annual Meeting, in Falmouth, Massachusetts, June 2 through 4, 2016; and the 32nd Annual Meeting of the Northeastern Society of Plastic Surgeons, in Philadelphia, Pennsylvania, September 18 through 20, 2015.

Copyright © 2018 by the American Society of Plastic Surgeons

DOI: 10.1097/PRS.0000000000004988

Disclosure: The authors have no financial interest to declare in relation to the content of this article.

the overlying soft-tissue structure and nasolabial morphology. As expected, the Le Fort I maxillary advancement has been reported to influence nasal proportions.⁵⁻⁹ The resulting three-dimensional nasolabial soft-tissue changes can be predicted for advancements up to 10 mm, thus aiding in more accurate surgical outcomes and aesthetic results.⁶ Quantitative data on changes in the nasolabial region have been generated for sagittal advancement, and our group has evaluated these changes using three-dimensional photogrammetric data.^{6,10,11} There are currently no significant data on the three-dimensional nasal changes that occur with counterclockwise or clockwise lateral plane rotation [mostly, anterior (counterclockwise) or posterior (clockwise) maxillary impaction] during Le Fort I maxillary advancement.

The purpose of this study was to analyze and compare nasolabial soft-tissue changes after Le Fort I clockwise and counterclockwise movements using three-dimensional photometric measurements. We aimed to compare anthropometric nasolabial measurements from preoperative and postoperative three-dimensional photographs following clockwise or counterclockwise maxillary movements. We hypothesize that there is a difference in nasal morphologic change between the two groups.

PATIENTS AND METHODS

This was a retrospective cohort study performed in accordance with a protocol submitted to, and approved by, the Yale University Human Investigation Committee (no. 1101007932), of patients who underwent single-piece Le Fort I maxillary advancement, with matched surgical and orthodontic protocols. Patients were divided into two groups (counterclockwise and clockwise), based on the occlusal plane change and at least 1-year follow-up. Patients with segmented maxillary osteotomies or a history of surgery to the nose, lip, or midface were excluded.

Preoperative and postoperative computed tomographic images were compared for bony movements, including degree of advancement and rotation. Preoperative and postoperative three-dimensional photogrammetric data were captured using the VECTRA 3D photosystem (Canfield Scientific, Fairfield, N.J.) in concordance with the senior author's previous studies (Figs. 1 and 2).^{10,12} Nasolabial anthropometric measurements were performed using the three-dimensional postprocessing software (Mirror; Canfield) with standard cephalometric point analysis (Table 1).

Measurements included nasal tip projection, alar base width, alar distance, nostril sill distance, lip length, and projection (Table 2). Two blinded reviewers independently marked and verified these landmarks for consistent measurements.

Statistical analysis was performed using Stata version 12.0 (StataCorp LP, College Station, Texas). The paired *t* test was used to compare differences between the clockwise and counterclockwise groups. The independent sample *t* test was used to compare the change in percentage between the two groups. Alpha = 0.05 was our level of significance throughout.

RESULTS

Twenty-four patients with preoperative and postoperative three-dimensional photographic data sets were included (clockwise, *n* = 12; counterclockwise, *n* = 12). The male-to-female ratio and mean age were 0.5 and 24.9 years, respectively, for the clockwise group; and 0.09 and 18.0 years, respectively, for the counterclockwise group, with no statistical difference between groups. The average follow-up time for three-dimensional photographs was 12.2 months postoperatively for the clockwise group and 17 months for the counterclockwise group, without a significant difference. Mean advancement was of 4.8 ± 1.7 mm with mean rotation of 4 ± 1.3 mm for the clockwise group, and 4.6 ± 1.36 mm with mean rotation of -4.2 ± 1.6 mm for the counterclockwise group. Mean follow-up time was 12.2 months for the clockwise group and 17 months for the counterclockwise group. Average advancement and rotation were statistically identical between both movements (*p* = 0.864 and *p* = 0.531). There was no significant difference in the number of patients receiving an alar cinch, and all patients in both groups underwent V-Y tubercle-plasty.

In the clockwise group, there were no significant soft-tissue changes preoperatively and postoperatively (Table 3). However, changes in alar base width and right nostril height approached significance (Fig. 3). Mean alar base width was 30.3 ± 2.7 mm preoperatively and increased to 32.1 ± 2.4 mm postoperatively (8.89 percent change; *p* = 0.09). Mean right nostril height was 13.1 ± 1.6 mm preoperatively and decreased to 12.0 ± 1.43 mm postoperatively (-8.39 percent change; *p* = 0.09).

With regard to the counterclockwise group, significant changes were seen in alar base width, alar width, mouth width, and superior lip projection (Table 4). Mean alar base width was 18.8 ± 1.3 mm preoperatively and increased significantly

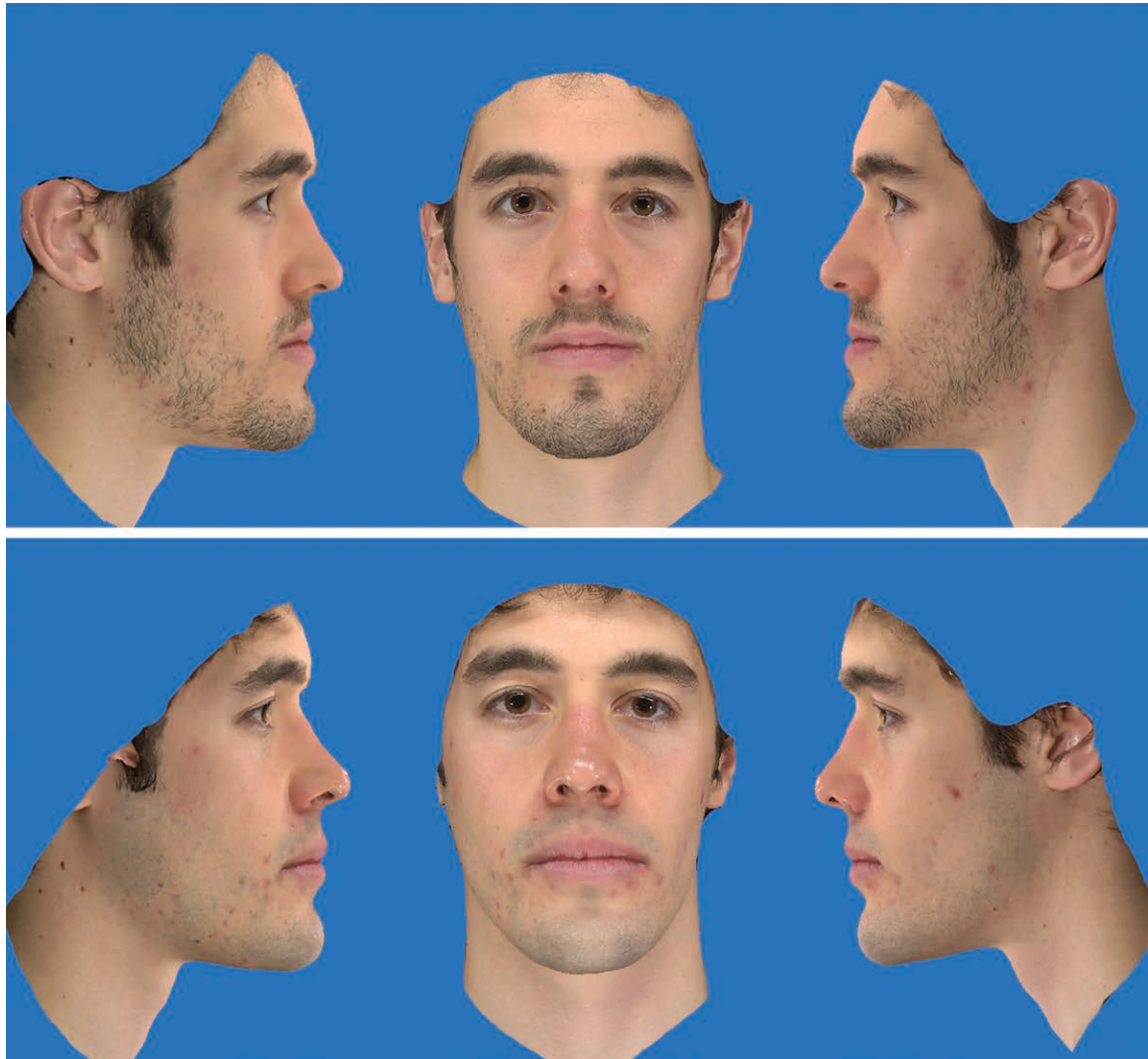

Fig. 1. VECTRA 3D soft-tissue images before (*above*) and after (*below*) maxillary advancement with clockwise rotation.

Table 1. Landmarks Used for Three-Dimensional Nasolabial Soft-Tissue Assessment

Landmark	Abbreviation	Definition
Glabella	G	Most anteriorly projected point of the forehead within the midsagittal plane
Nasion	N	Most depressed midline point superior to the nasal bridge
Alare	Al	Most lateral point of the alar contour
Subalare	SA	Labial insertion of each alar base
Pronasale	Prn	Most anterior point of the nose
Columella peak	CP	Most superior point of the columella
Subnasale	Sn	Midpoint of the nasolabial angle at the columellar base
Medial nostril base	mNb	Point on inner nostril where the columella meets the columellar crest
Lateral nostril base	lNb	Most inferolateral point of the nostril
Lateral alar	LA	Point on inner nostril rim at its labial insertion
Soft triangle	ST	Most superomedial point of the nostril
Midcolumella	MC	Medial nostril point at midcolumella height level
Lateral crus	LC	Perpendicular to the columella, through the midcolumella on the lateral crus
Crista philtri superior	Cphs	Top of the philtral crest at the level of the subnasale
Labiale superius	Ls	Midpoint of the upper vermillion border
Crista philtri inferior	Cphi	Point of maximum vertical height of the upper vermillion border (Cupid's bow)
Chelion	Che	Most lateral point of the labial commissure
Tragus	Tr	Most anterior point of the tragus

Table 2. Parameters (Direct Distances and Angles) Used for Three-Dimensional Nasolabial Soft-Tissue Assessment

Measurement	Abbreviation	Definition
Nose		
Nasofrontal angle	NFA	Angle between G, N, and Prn
Nasolabial angle	NLA	Angle between CP, Sn, and Ls
Nasal tip projection	NP	Distance between Tr and Prn
Alar base width	ABW	Distance between SA (left) and SA (right)
Alar width	ACW	Distance between Al (left) and Al (right)
Sill width		
Right	SWr	Distance between mNb and INb (right)
Left	SWl	Distance between mNb and INb (left)
Nostril height		
Right	NHr	Distance between LA and ST (right)
Left	NHl	Distance between LA and ST (left)
Nostril width		
Right	Nwr	Distance between MC and Al (right)
Left	Nwl	Distance between MC and Al (left)
Soft triangle angle		
Right	STAR	Angle between MC, ST, and LC (right)
Left	STAL	Angle between MC, ST, and LC (left)
Columella width	CW	Distance between MC (right) and MC (left)
Columella height	CH	Distance between Sn and CP
Columella projection	CP	Distance between Tr and CP
Lip		
Subnasale projection	SnP	Distance between Tr and Sn
Lower philtrum width	LPW	Distance between Cphi (right) and Cphi (left)
Upper philtrum width	UPW	Distance between Cphs (right) and Cphs (left)
Philtrum height	PH	Distance between Ls and Sn
Mouth width	MW	Distance between Che (right) and Che (left)
Labial superius projection	LSP	Distance between Tr and Ls

Table 3. Morphometric Evaluation before and after Maxillary Advancement with Clockwise Rotation

CW Measurements	T1 (mm)	T2 (mm)	Δ T2-T1 (mm)	<i>p</i>
Nose				
Nasofrontal angle	143.7 ± 6.8	141.2 ± 7.2	-2.6 ± 4.3	0.38
Nasolabial angle	111.2 ± 11.1	113.4 ± 7.5	2.3 ± 7.6	0.56
Nasal tip projection	128.4 ± 5.8	129.4 ± 6.5	1.0 ± 1.33	0.70
Alar base width	30.3 ± 2.7	32.1 ± 2.4	1.8 ± 1.7*	0.09*
Alar width	32.8.1 ± 3.2	35.4 ± 4.3	2.63 ± 2.31	0.10
Sill width				
Right	8.2 ± 1.1	8.6 ± 1.5	0.4 ± 1.6	0.48
Left	8.1 ± 1.2	8.4 ± 1.33	0.3 ± 1.2	0.62
Nostril height				
Right	13.1 ± 1.6	12.0 ± 1.43	-1.1 ± 0.7*	0.09*
Left	13.1 ± 1.8	12.6 ± 1.64	-0.5 ± 0.8	0.44
Nostril width				
Right	9.1 ± 2.4	9.7 ± 2.2	0.6 ± 0.8	0.51
Left	9.5 ± 1.9	10.4 ± 2.21	0.8 ± 0.9	0.33
Soft triangle angle				
Right	78.9 ± 12.2	86.5 ± 15.7	7.6 ± 9.8	0.20
Left	85.1 ± 13.11	90.5 ± 14.4	5.4 ± 9.8	0.34
Columella width	6.2 ± 0.6	6.2 ± 0.7	0.00 ± 0.63	1.00
Columella height	9.7 ± 1.85	9.08 ± 1.82	-0.7 ± 1.0	0.40
Columella projection	124.2 ± 6.0	125.9 ± 6.6	1.7 ± 2.4	0.52
Lip				
Subnasion projection	118.12 ± 5.9	120.2 ± 6.5	2.5 ± 1.95	0.41
Lower philtrum width	12.1 ± 1.6	12.8 ± 3.2	0.7 ± 2.0	0.53
Upper philtrum width	7.4 ± 1.4	7.9 ± 2.0	0.4 ± 1.7	0.53
Philtrum height	15.4 ± 3.5	16.08 ± 3.61	0.7 ± 1.4	0.65
Mouth width	50.2 ± 5.1	52.7 ± 6.0	2.5 ± 2.9	0.28
Labiale superius projection	122.5 ± 6.5	125.6 ± 8.0	3.0 ± 2.7	0.32

CW, clockwise; T1, preoperative; T2, postoperative.

*Statistically significant.

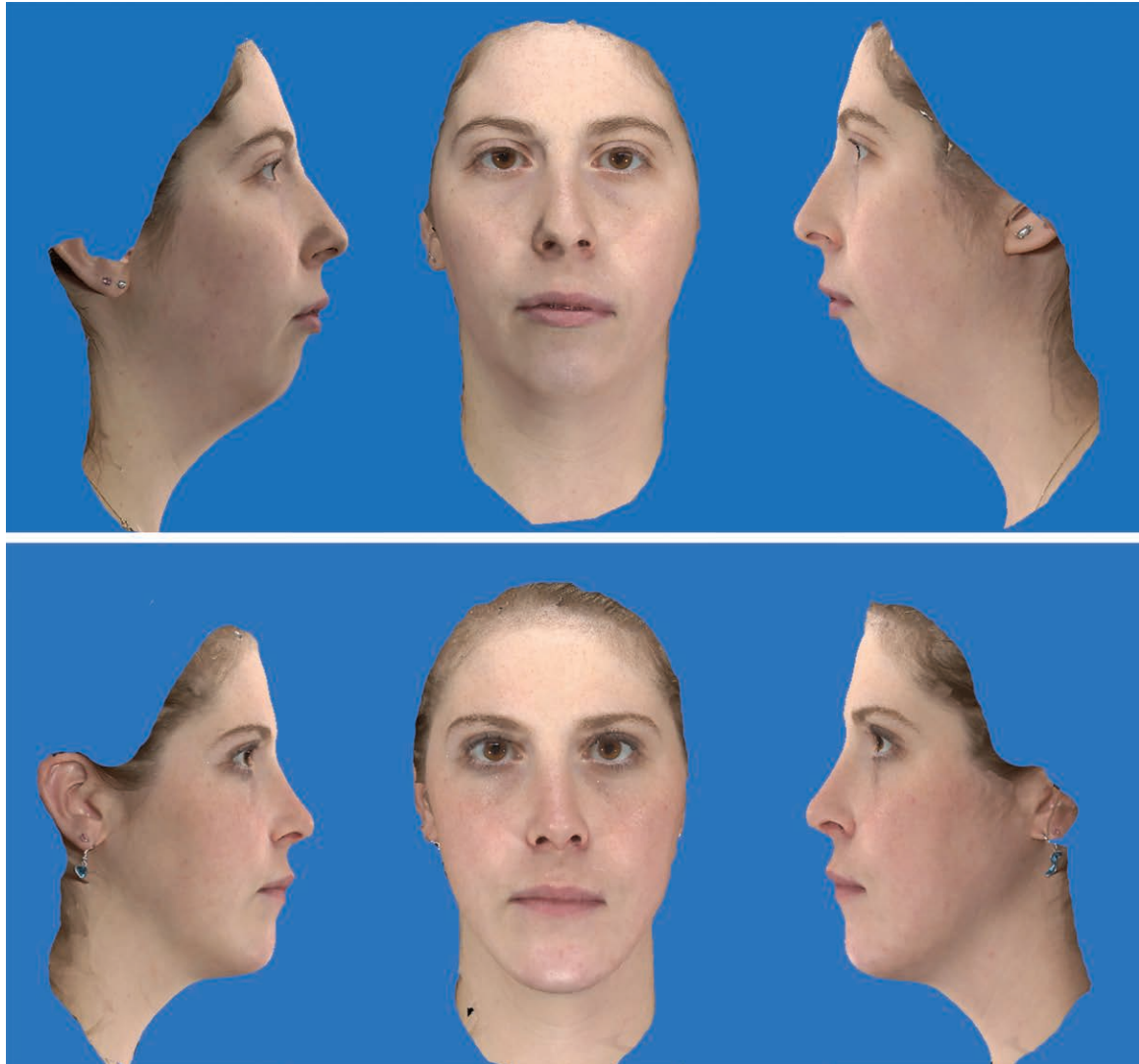

Fig. 2. VECTRA 3D soft-tissue images before (*above*) and after (*below*) maxillary advancement with counterclockwise rotation.

to 20.33 ± 1.4 mm postoperatively (8.44 percent change; $p = 0.009$) (Fig. 4 and Table 5). Mean alar width was 29.4 ± 1.07 mm preoperatively and increased significantly to 32.9 ± 2.07 mm postoperatively (12.07 percent change; $p < 0.001$). Mean mouth width significantly increased from 44.85 ± 2.6 mm to 48.01 ± 3.6 mm preoperatively and postoperatively (1.24 percent change; $p = 0.0228$). Mean superior labial projection increased significantly from 116.24 ± 3.8 mm to 119.61 ± 3.74 mm preoperatively and postoperatively (8.44 percent change; $p = 0.0387$) (Fig. 5). Changes in columella width and subnasion projection approached significance. Columella width increased from 5.19 ± 0.9 mm to 5.77 ± 0.5 mm (8.44 percent change; $p = 0.0642$). Subnasion projection increased from 113.9 ± 3.4 mm to 116.3 ± 2.9 mm ($p = 0.0846$).

DISCUSSION

Le Fort I osteotomies remedy a wide range of midface deformities, permitting maxillary advancement, retrusion, elongation, shortening, impaction, and rotation.^{2,13–15} Despite its historic reliability, there is inconsistency in prediction of soft-tissue response to alterations in the underlying skeletal structure. Adverse reactions include but are not limited to thinning and lateral retraction of the lip, reduced vermilion exposure, increased nasolabial angle, and accentuation of the nasolabial groove. These changes are prevalent throughout the midface and are particularly notable in the morphology of the nasolabial region.⁶

Understanding and quantitatively estimating changes in the overlying soft tissue will permit superior patient counseling, and ultimately

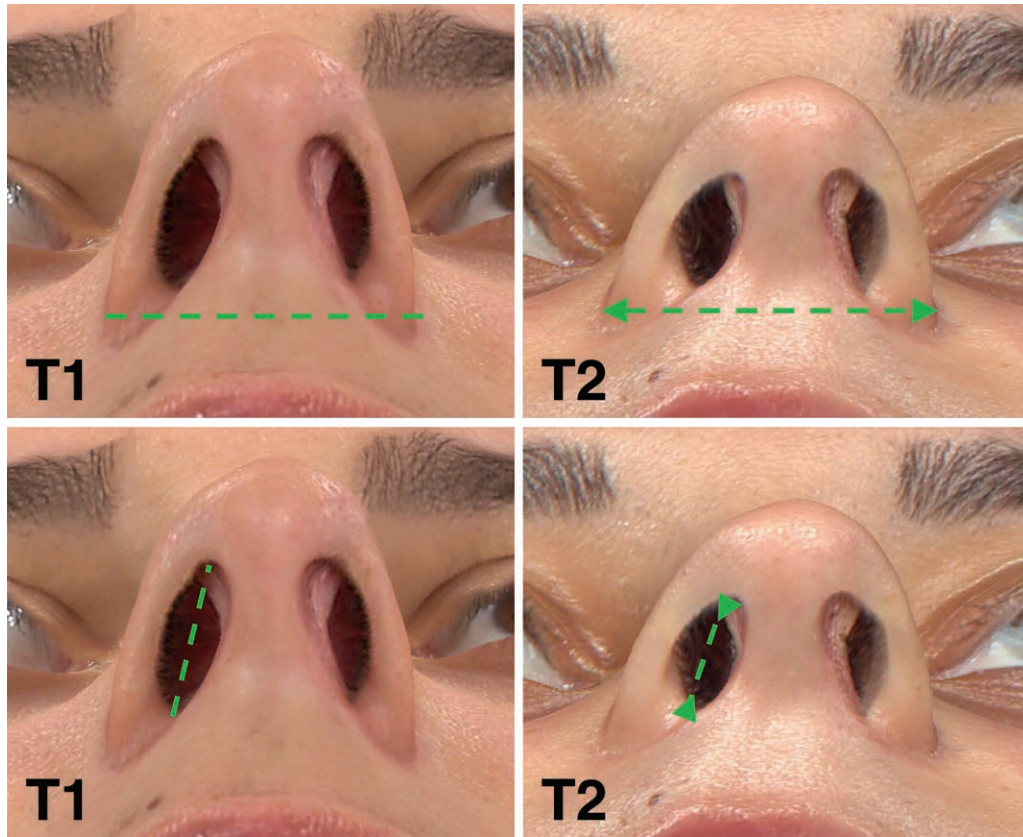


Fig. 3. VECTRA 3D images before (left) and after (right) maxillary advancement with clockwise rotation. (Above) Alar base width increases from 30.3 mm to 32.1 mm after advancement ($p = 0.09$). (Below) Right nostril height decreases from 13.1 mm to 12.0 mm after advancement ($p = 0.09$).

Table 4. Morphometric Evaluation before and after Maxillary Advancement with Counterclockwise Rotation

CCW Measurement	T1 (mm)	T2 (mm)	Δ T2-T1 (mm)	<i>p</i>
Nose				
Nasofrontal angle	152.2 ± 4.2	149.1 ± 4.7	-3.1 ± 3.0	0.11
Nasolabial angle	117 ± 9.5	113.8 ± 13.6	-3.2 ± 8.8	0.51
Nasal tip projection	124.7 ± 4.4	126.3 ± 4.3	1.55 ± 3.2	0.39
Alar base width	18.8 ± 1.3	20.33 ± 1.4	1.6 ± 0.9*	0.009*
Alar width	29.4 ± 1.07	32.9 ± 2.07	3.55 ± 1.9*	<0.001*
Sill width				
Right	7.8 ± 1.2	8.2 ± 0.7	0.33 ± 0.8	0.41
Left	7.7 ± 0.9	8.1 ± 0.9	0.32 ± 0.6	0.44
Nostril height				
Right	12.8 ± 1.3	12.0 ± 1.51	-0.7 ± 0.92	0.227
Left	13.02 ± 1.2	12.4 ± 1.5	-0.7 ± 0.7	0.25
Nostril width				
Right	8.67 ± 1.8	9.59 ± 1.4	0.9 ± 1.6	0.1818
Left	8.71 ± 1.59	9.74 ± 1.4	1.03 ± 1.51	0.1074
Soft triangle angle				
Right	81.9 ± 13.9	89.2 ± 11.7	7.23 ± 19.4	0.1839
Left	80.15 ± 15.5	91.2 ± 16.9	11.03 ± 7.83	0.1097
Columella width	5.19 ± 0.9	5.77 ± 0.5	0.58 ± 0.9*	0.0642*
Columella height	10.0 ± 2.0	9.89 ± 1.73	-0.11 ± 1.19	0.8887
Columella projection	120.89 ± 4.08	122.94 ± 3.9	2.05 ± 2.6	0.2221
Lip				
Subnasion projection	113.9 ± 3.4	116.3 ± 2.9	2.33 ± 2.9*	0.0846*
Lower philtrum width	10.8 ± 2.5	12.5 ± 2.3	1.63 ± 2.76	0.1121
Upper philtrum width	6.575 ± 1.87	7.325 ± 1.7	0.75 ± 2.4	0.3138
Philtrum height	15.16 ± 2.9	15.08 ± 2.7	-0.083 ± 1.4	0.9426
Mouth width	44.85 ± 2.6	48.01 ± 3.6	3.17 ± 2.9*	0.0228*
Labiale superius projection	116.24 ± 3.8	119.61 ± 3.74	3.37 ± 2.9*	0.0387*

CCW, counterclockwise; T1 preoperative; T2 postoperative.

*Statistically significant.

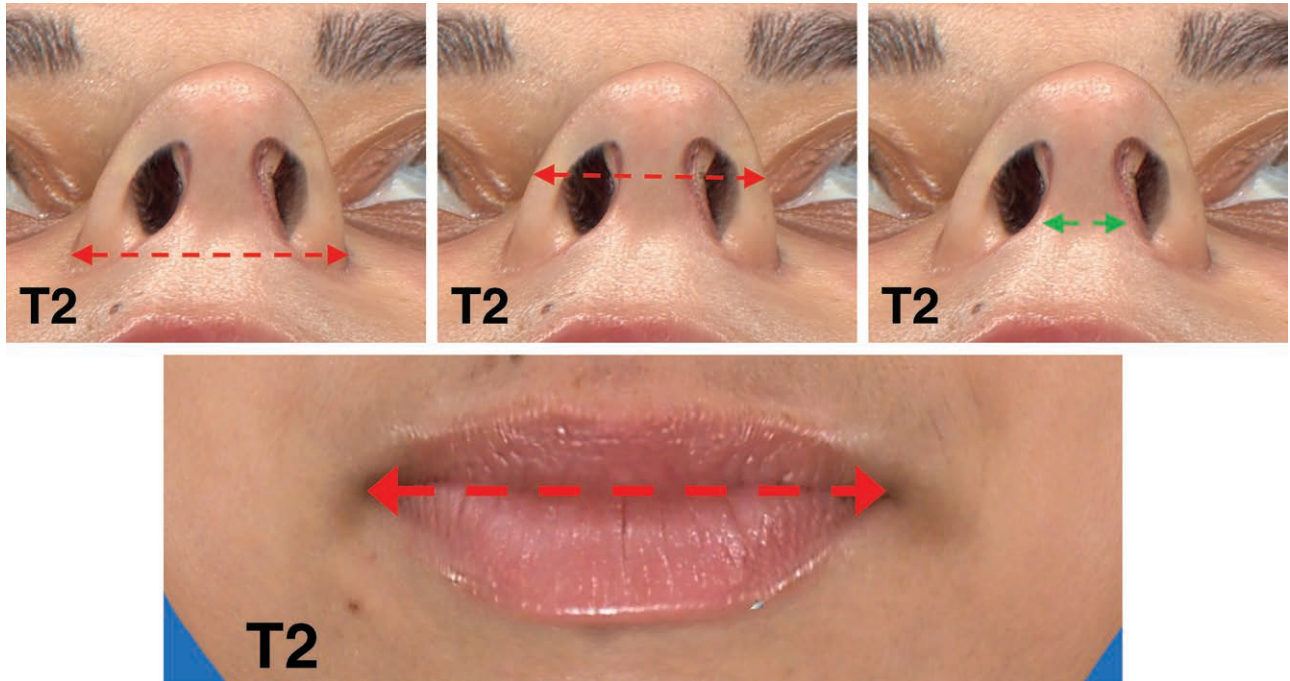


Fig. 4. VECTRA 3D images after (T2) maxillary advancement with counterclockwise rotation. (Above, left) Alar base width increases from 18.8 mm to 20.3 mm after advancement ($p = 0.009$). (Above, right) Alar width increases from 29.4 mm to 32.9 mm after advancement ($p < 0.001$). (Below, left) Columella width increases from 5.2 mm to 5.8 mm ($p = 0.064$). (Below, right) Mouth width increases from 44.9 mm to 48.0 mm ($p = 0.023$).

Table 5. Percentage Changes following Clockwise and Counterclockwise Rotation

	Change (%)		<i>p</i>	
	CW	CCW	CW	CCW
Nose				
Nasofrontal angle	-1.78	-2.00	0.38	0.11
Nasolabial angle	2.04	-2.72	0.56	0.51
Nasal tip projection	0.76	1.24	0.70	0.39
Alar base width	8.89	8.44	0.09	0.009
Alar width	8.03	12.07	0.10	<0.001
Sill width				
Right	4.80	4.26	0.48	0.41
Left	3.17	4.08	0.62	0.44
Nostril height				
Right	-8.39*	-5.66	0.09*	0.227
Left	-2.00	-2.00	0.44	0.25
Nostril width				
Right	-2.72	-2.72	0.51	0.1818
Left	1.24	1.24	0.33	0.1074
Soft triangle angle				
Right	8.44	8.44	0.20	0.1839
Left	-2.00	-2.00	0.34	0.1097
Columella width	8.44	8.44*	1.00	0.0642
Columella height	-2.00	-2.00	0.40	0.8887
Columella projection	-2.72	-2.72	0.52	0.2221
Lip				
Subnasion projection	1.24	1.24*	0.41	0.0846*
Lower philtrum width	8.44	8.44	0.53	0.1121
Upper philtrum width	-2.00	-2.00	0.53	0.3138
Philtrum height	-2.72	-2.72	0.65	0.9426
Mouth width	1.24	1.24*	0.28	0.0228*
Labiale superius projection	8.44	8.44*	0.32	0.0387*

CW, clockwise; CCW, counterclockwise.

*Statistically significant.

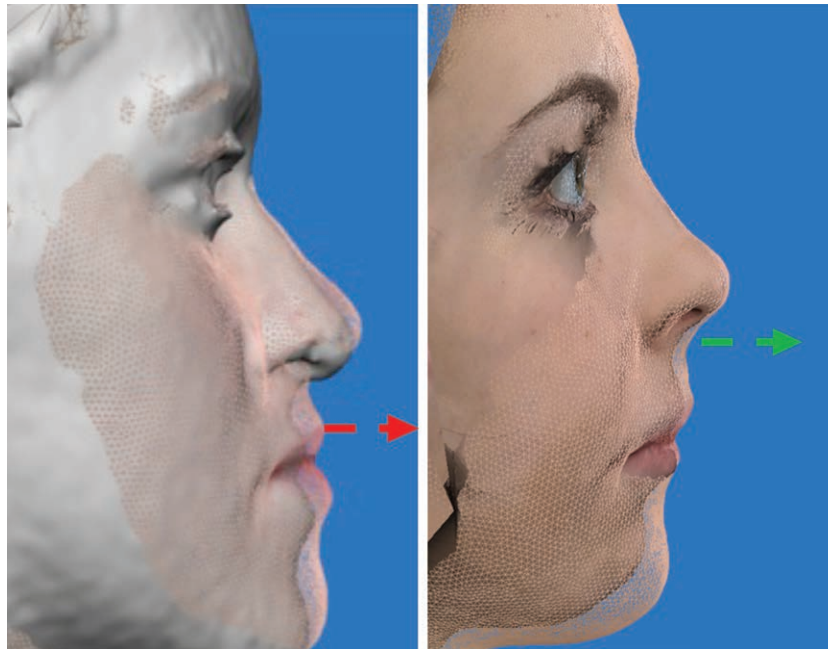


Fig. 5. VECTRA 3D images after (T2) maxillary advancement with counterclockwise rotation. (Left) Labial superioris projection increases from 116.2 mm to 119.6 mm after advancement ($p = 0.039$). (Right) Subnasion projection increases from 113.9 mm to 116.3 mm ($p = 0.085$).

improve or predict aesthetic outcomes. Postoperative two-dimensional soft-tissue changes in response to maxillary surgery have been documented in the literature in hopes of creating a reference for surgical planning. These predictions, however, inherently lack the ability to quantify the complex three-dimensional changes that are essential to facial morphology, and many vantage points (including the frontal plane) are missed. Conventional two-dimensional photography is also limited because of the measurement scaling based on image magnification, decreasing concordance and accuracy. Three-dimensional imaging provides the most reliable, complete, and predictable data.

The VECTRA 3D photogrammetric surface imaging system used to capture patient images was selected as a radiation-free modality for assessing nasolabial morphology.^{16–18} Validity studies have shown that three-dimensional photometric capture exhibits excellent reliability and reproducibility in facial anthropometric measurements.^{16,17} In addition, data can be collected rapidly and archived for later use should further retrospective analysis be conducted. Alternative methods, such as direct anthropometry, moiré, laser, and volumetric computed tomography do not have comparable technical accuracy, surface texture, or resolution.¹⁶ Furthermore, direct measurements

are highly examiner dependent, and there is no possibility of systematic retrospective analysis.

The current study is the next in a series focused on analyzing three-dimensional cephalometric soft-tissue changes following orthognathic operations. Our previous corollary study assessed three-dimensional changes exclusively in Le Fort I advancement without other movements and documented significant changes in nasolabial metrics, including alar base, alar width, nostril width, nasal tip, columella, and upper lip projection.⁶ This preliminary analysis laid the groundwork for a detailed assessment of advancement with clockwise or counterclockwise rotation.

Clockwise rotations that surgically increase the occlusal plane are advantageous for achieving midface fullness in patients with strong lower jaws that follow the class III growth pattern.^{19,20} Counterclockwise rotations surgically decrease the occlusal plane, helping normalize lower anterior facial height, increase posterior facial height, and can be incorporated with advancements to increase airflow.²¹ Our prior work demonstrates that three-dimensional soft-tissue changes were consistent and could be reproducible for maxillary advancements up to 10 mm⁶. Thus, 4.6- and 4.8-mm clockwise and counterclockwise advancements, respectively, fall within appropriate limits for comparison.

The Le Fort sagittal advancement alone creates a baseline nasolabial morphometric change such as alar widening, lip shortening, and decreased nasolabial angle.^{8,22} However, we wished to understand the minor alterations imparted by the addition of occlusal plane rotation. As expected, all significant (or nearly significant) changes in the clockwise or counterclockwise groups increased or decreased parallel to the change seen in pure maxillary advancement with the exception of columella width.⁶ Columella width increased, although not significantly, in counterclockwise rotation by 0.58 ± 0.9 mm (compared to a small decrease in pure advancement). However, this fell within the confidence interval (-0.9 to 0.6 mm) of the advancement study's values.

All significant changes and borderline significant values in both groups fell within the confidence interval of changes in the advancement study. Mouth width increased by 3.17 ± 2.9 mm in the counterclockwise group and increased by 2.5 ± 2.9 mm in the clockwise group, but not significantly. Mouth width is expected to increase, secondary to forward bony advancement and resulting increase in tissue tension and drape. Labial parameters tend to undergo the most substantial change because of the proximity of the mouth to the maxilla, and additional movements, such as impaction, may exacerbate changes.²³ As discussed earlier, counterclockwise rotation creates exaggerated anterior maxillary alteration as compared to clockwise rotation and, as expected, likely caused increased change in mouth width.

Clockwise or counterclockwise rotations impacted nasolabial changes differently in our cohort. We observed significant shifts in nose and lip measurements with counterclockwise rotation but not clockwise rotation. Considering the influence at the piriform level likely explains this difference. Clockwise movement involves either no or increased vertical distance at the piriform (from posterior impaction and/or anterior lengthening),²⁴ and only the sagittal advancement magnitude changes the nasolabial angle. Counterclockwise repositioning entails anterior impaction (and possibly some posterior vertical lengthening), which decreases the vertical distance at the piriform, in addition to the expected sagittal advancement influences.

Both bony and soft-tissue alterations impact the alar base. Changes to the alar base are likely in response to the underlying maxilla and piriform,^{22,25} but also result from the splay and drape following subperiosteal release and separation of the lateral nasal muscle attachments.

Confounding variables to this study include the amount of piriform modification, plate positioning, alar cinching, and closure. However, these strategies were employed in a similar fashion in each cohort, and did not demonstrate statistically significant differences in the rate of use of these adjunctive procedures between the two groups (data not shown). In addition, during the period that passed for follow-up (at least 1 year), the soft-tissue acclimation and stabilization had occurred, reaching a steady state. The alar cinch has been shown to relax with time,²³ and does not obviate the untoward widening that can occur with maxillary advancement and/or anterior impaction. Such a suture was used in all our cases, with the goal being the medial-intercanthal distance. With application across both clockwise and counterclockwise groups, in an equivalent manner all performed by the senior author, we believe the confounding effect in the final nasolabial and alar base positions to be minimized and equivalent between the compared groups. Similarly, a V-Y tubercle-plasty of the upper lip mucosa/vermillion maintains upper lip fullness. This was performed in the entirety of the cohorts, also of similar magnitude (5 mm), limiting its confounding effect on the reported data.

The ideal time at which to assess morphologic changes following orthognathic surgery is at least 12 months postoperatively, once edema has diminished and healing has occurred. Traditionally, this was done using cephalography. Le Fort I stability data suggest that horizontal and vertical soft tissue results at 1 year are similar to those long term.²⁶ We chose to record three-dimensional measurements at 12 months postoperatively to ensure this period had been reached. In the future, it may be beneficial to record measurements at longer follow-up periods (e.g., 2 and 4 years) to capture and confirm final soft-tissue equilibrium.

The objective of this study was to detail and compare nasolabial soft-tissue changes following Le Fort I advancement with clockwise or counterclockwise rotation. Although we adequately powered our sample size, we acknowledge our numbers are small. It is possible that measurements approaching but not achieving significance, such as alar base width and nostril height in the clockwise group, are truly significant in a larger sample size. Completely controlling all possible variables in these complex, multifactorial procedures is challenging; however, the data in this study represent an optimally available cohort of patient outcomes that have allowed for the complex evaluation of

long-term soft-tissue changes between two important variables in orthognathic surgery.

We hope that our data will guide treatment decisions and patient expectations moving forward. Physicians may opt to counsel patients receiving a counterclockwise rotation on the predicted nose and lip changes documented in this study. Discussion may be appropriate here between physicians and patients on the possible need for rhinoplasty if the predicted nasal morphology is not desired. As changes are anticipated, a concurrent rhinoplasty can be offered to mitigate additional operations. Future work should focus on the exact magnitude of soft-tissue changes expected for every millimeter of advancement/rotation, in hopes of building a template for appropriate three-dimensional planning and modeling.

CONCLUSIONS

Three-dimensional morphometric nasolabial changes are different in clockwise versus counterclockwise Le Fort I movements. Counterclockwise repositioning imparts a significant change regarding alar width, alar base width, oral width, and lip projection. Recognition of the greater alar changes following counterclockwise movements is important for predication, treatment planning, and patient counseling.

Derek M. Steinbacher, M.D., D.M.D.
 Department of Surgery
 Section of Plastic Surgery
 Yale University School of Medicine
 P.O. Box 8041
 New Haven, Conn. 06520-8062
 derek.steinbacher@yale.edu

PATIENT CONSENT

Patients provided written consent for the use of their images.

REFERENCES

- Cousley RR, Grant E. The accuracy of preoperative orthognathic predictions. *Br J Oral Maxillofac Surg.* 2004;42:96–104.
- Buchanan EP, Hyman CH. Le Fort I osteotomy. *Semin Plast Surg.* 2013;27:149–154.
- Scolozzi P. Distraction osteogenesis in the management of severe maxillary hypoplasia in cleft lip and palate patients. *J Craniofac Surg.* 2008;19:1199–1214.
- Konstantos KA, O'Reilly MT, Close J. The validity of the prediction of soft tissue profile changes after LeFort I osteotomy using the dentofacial planner (computer software). *Am J Orthod Dentofacial Orthop.* 1994;105:241–249.
- Schendel SA, Williamson LW. Muscle reorientation following superior repositioning of the maxilla. *J Oral Maxillofac Surg.* 1983;41:235–240.
- Metzler P, Geiger EJ, Chang CC, Sirisoontorn I, Steinbacher DM. Assessment of three-dimensional nasolabial response to Le Fort I advancement. *J Plast Reconstr Aesthet Surg.* 2014;67:756–763.
- Bailey LJ, Collie FM, White RP Jr. Long-term soft tissue changes after orthognathic surgery. *Int J Adult Orthodon Orthognath Surg.* 1996;11:7–18.
- Rosen HM. Lip-nasal aesthetics following Le Fort I osteotomy. *Plast Reconstr Surg.* 1988;81:171–182.
- McFarlane RB, Frydman WL, McCabe SB, Mamandras AM. Identification of nasal morphologic features that indicate susceptibility to nasal tip deflection with the LeFort I osteotomy. *Am J Orthod Dentofacial Orthop.* 1995;107:259–267.
- Metzler P, Geiger EJ, Chang CC, Steinbacher DM. Surgically assisted maxillary expansion imparts three-dimensional nasal change. *J Oral Maxillofac Surg.* 2014;72:2005–2014.
- Vasudavan S, Jayaratne YS, Padwa BL. Nasolabial soft tissue changes after Le Fort I advancement. *J Oral Maxillofac Surg.* 2012;70:e270–e277.
- Metzler P, Geiger EJ, Chang CC, Sirisoontorn I, Steinbacher DM. Assessment of three-dimensional nasolabial response to Le Fort I advancement. *J Plast Reconstr Aesthet Surg.* 2014;67:756–763.
- Sarver DM, Weissman SM. Long-term soft tissue response to LeFort I maxillary superior repositioning. *Angle Orthod.* 1991;61:267–276.
- Rondahl US, Bystedt H, Enqvist B, Malmgren O. Changes after correction of maxillary retrusion by Le Fort I osteotomy: A comparison of 2 methods of skeletal fixation. *Int J Oral Maxillofac Surg.* 1988;17:165–169.
- Bell WH, McBride KL. Correction of the long face syndrome by Le Fort I osteotomy: A report on some new technical modifications and treatment results. *Oral Surg Oral Med Oral Pathol.* 1977;44:493–520.
- Metzler P, Bruegger LS, Kruse Gujer AL, et al. Craniofacial landmarks in young children: How reliable are measurements based on 3-dimensional imaging? *J Craniofac Surg.* 2012;23:1790–1795.
- Metzler P, Sun Y, Zemmann W, et al. Validity of the 3D VECTRA photogrammetric surface imaging system for cranio-maxillofacial anthropometric measurements. *Oral Maxillofac Surg.* 2014;18:297–304.
- de Menezes M, Rosati R, Ferrario VF, Sforza C. Accuracy and reproducibility of a 3-dimensional stereophotogrammetric imaging system. *J Oral Maxillofac Surg.* 2010;68:2129–2135.
- Posnick JC. *Principles and Practice of Orthognathic Surgery.* London: Elsevier Health Sciences; 2013.
- Strickland SL. *Long-Term Stability of LeFort I Maxillary Downgraft with Rigid Internal Fixation.* Birmingham, Ala: University of Alabama at Birmingham; 2015.
- Esteves LS, Ávila C, Medeiros PJ. Changes in occlusal plane through orthognathic surgery. *Dental Press J Orthod.* 2012;17:160–173.
- Betts NJ, Vig KW, Vig P, Spalding P, Fonseca RJ. Changes in the nasal and labial soft tissues after surgical repositioning of the maxilla. *Int J Adult Orthodon Orthognath Surg.* 1993;8:7–23.
- Farkas LG, Bryson W, Klotz J. Is photogrammetry of the face reliable? *Plast Reconstr Surg.* 1980;66:346–355.
- Hajeer MY, Ayoub AF, Millett DT. Three-dimensional assessment of facial soft-tissue asymmetry before and after orthognathic surgery. *Br J Oral Maxillofac Surg.* 2004;42:396–404.
- Schendel SA, Carlotti AE Jr. Nasal considerations in orthognathic surgery. *Am J Orthod Dentofacial Orthop.* 1991;100:197–208.
- Hack GA, de Mol van Otterloo JJ, Nanda R. Long-term stability and prediction of soft tissue changes after LeFort I surgery. *Am J Orthod Dentofacial Orthop.* 1993;104:544–555.